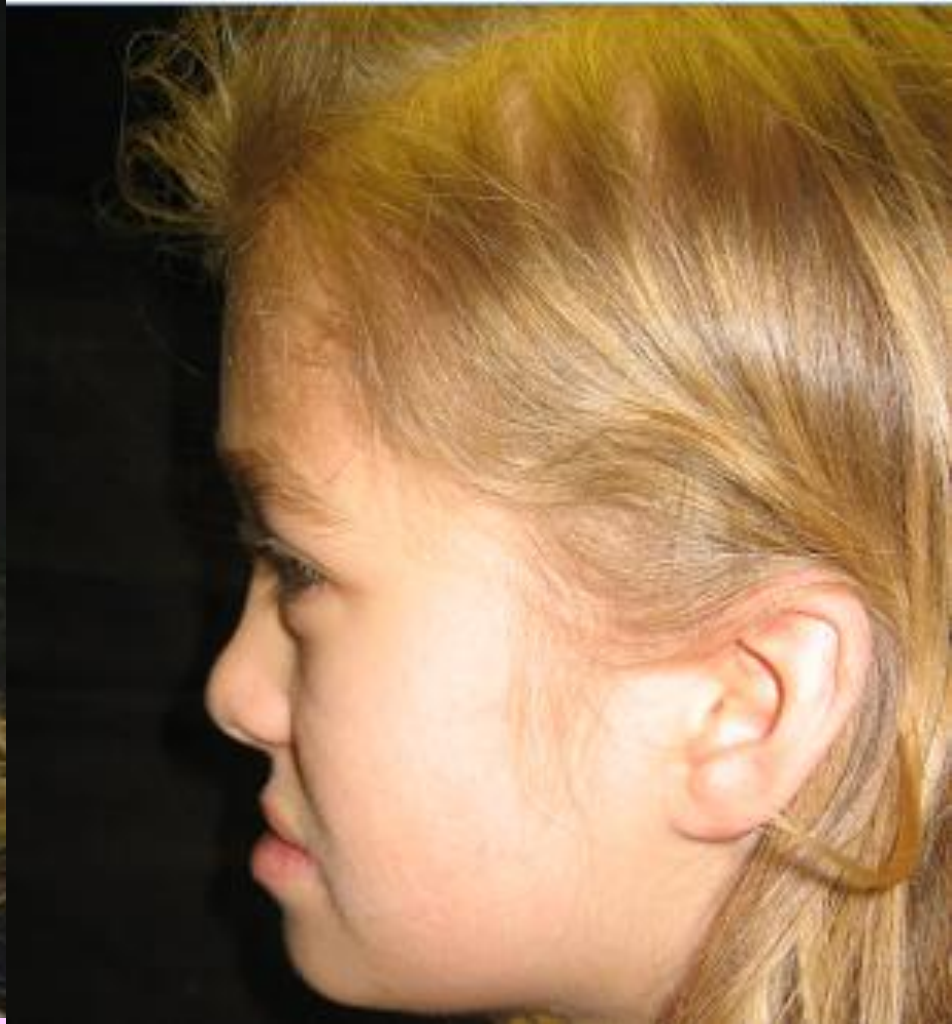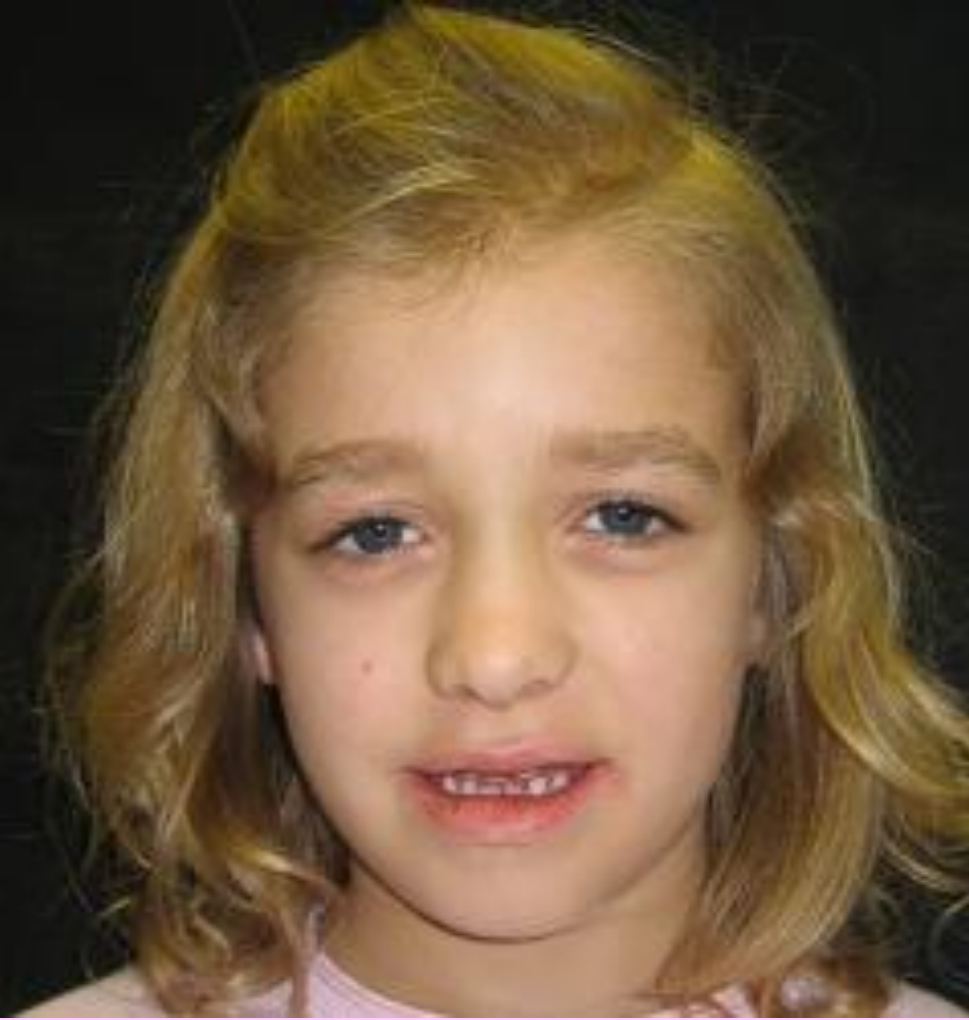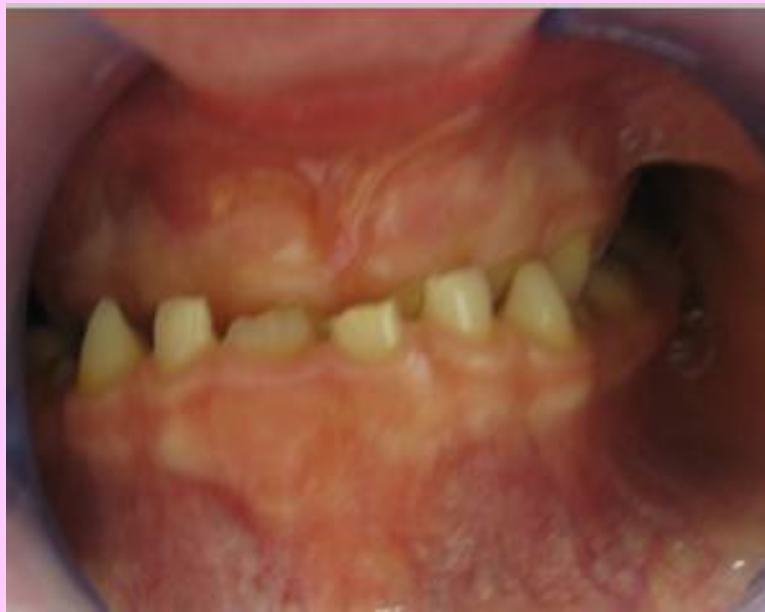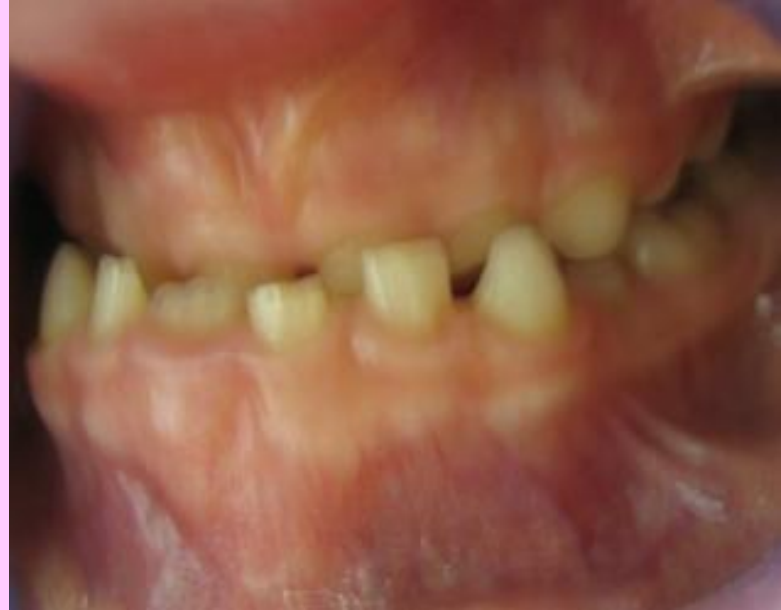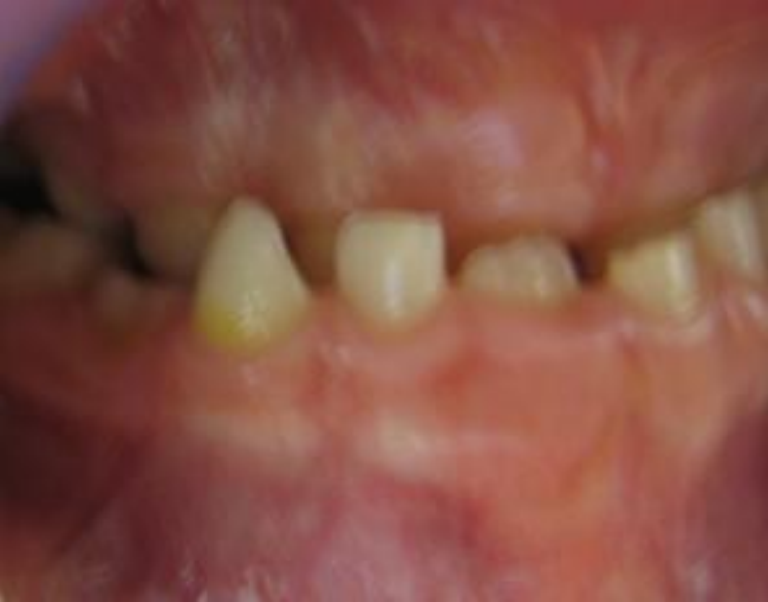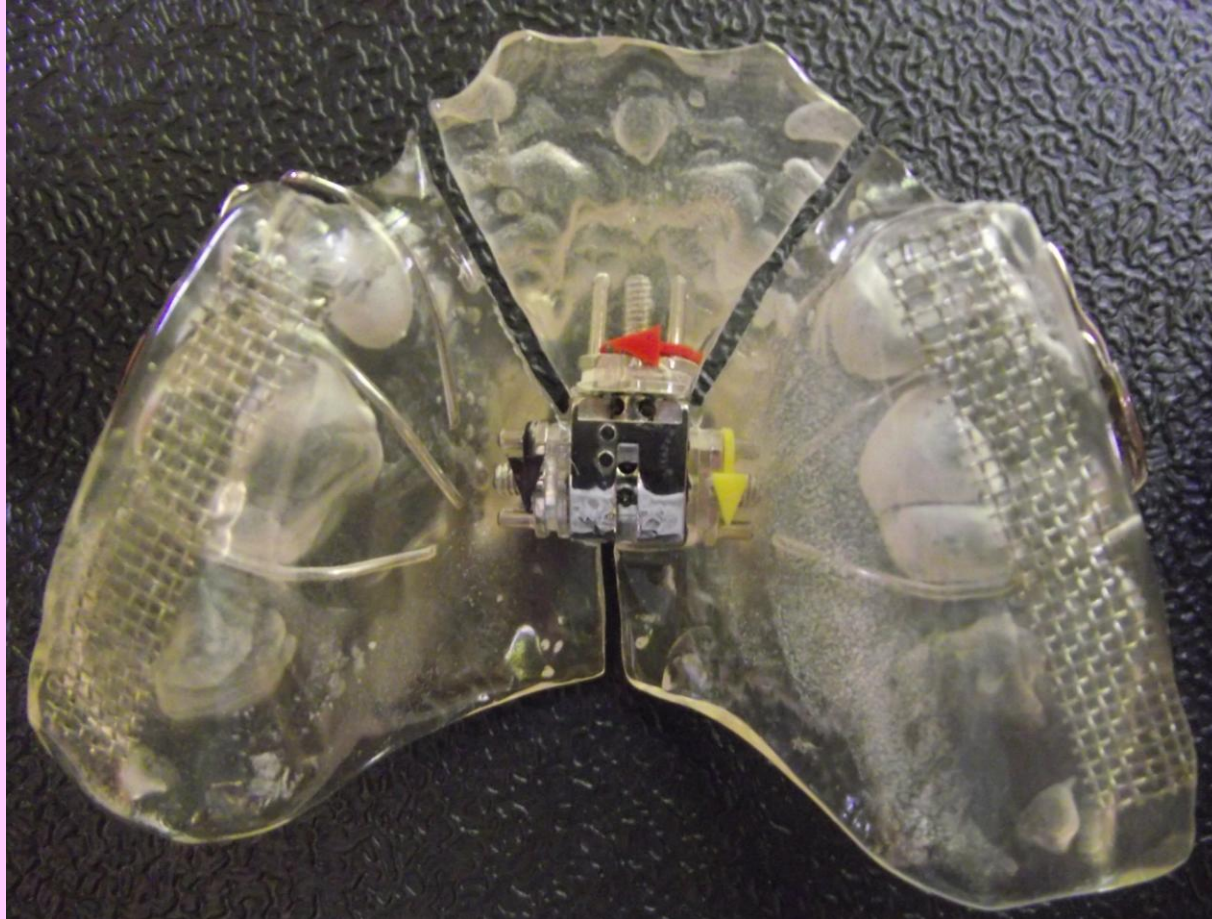




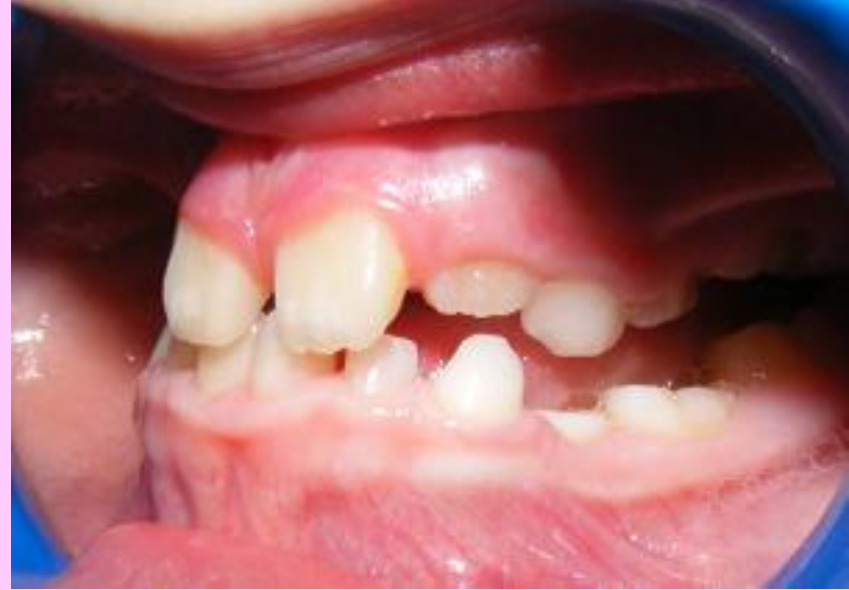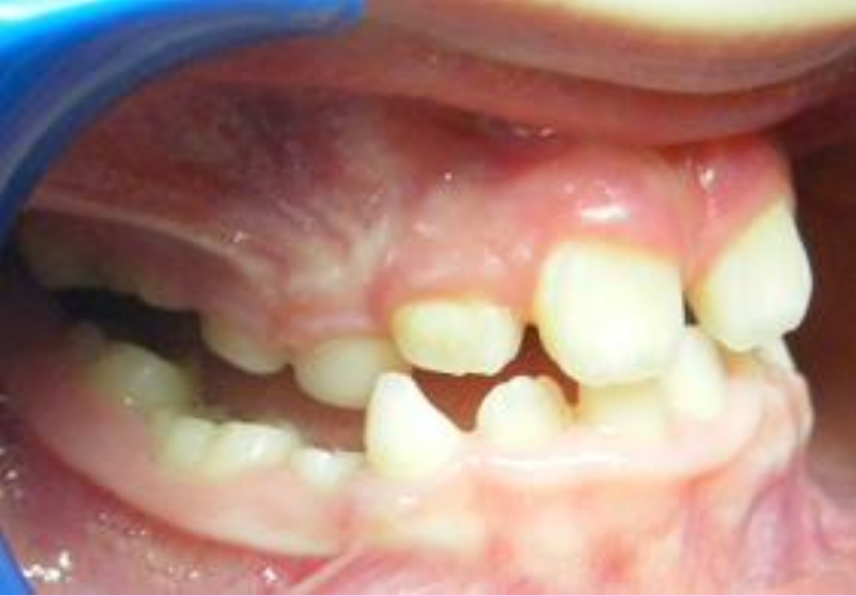This 9 year old girl with learning difficulties had an oversized lower Jaw and undeveloped upper jaw.



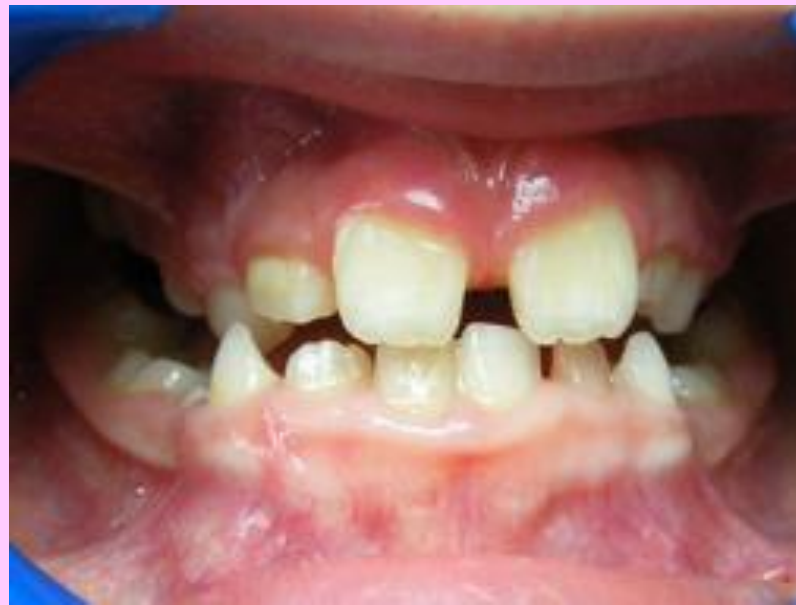With her teeth biting together the lowers are biting in front of the uppers in a bulldog type of bite.

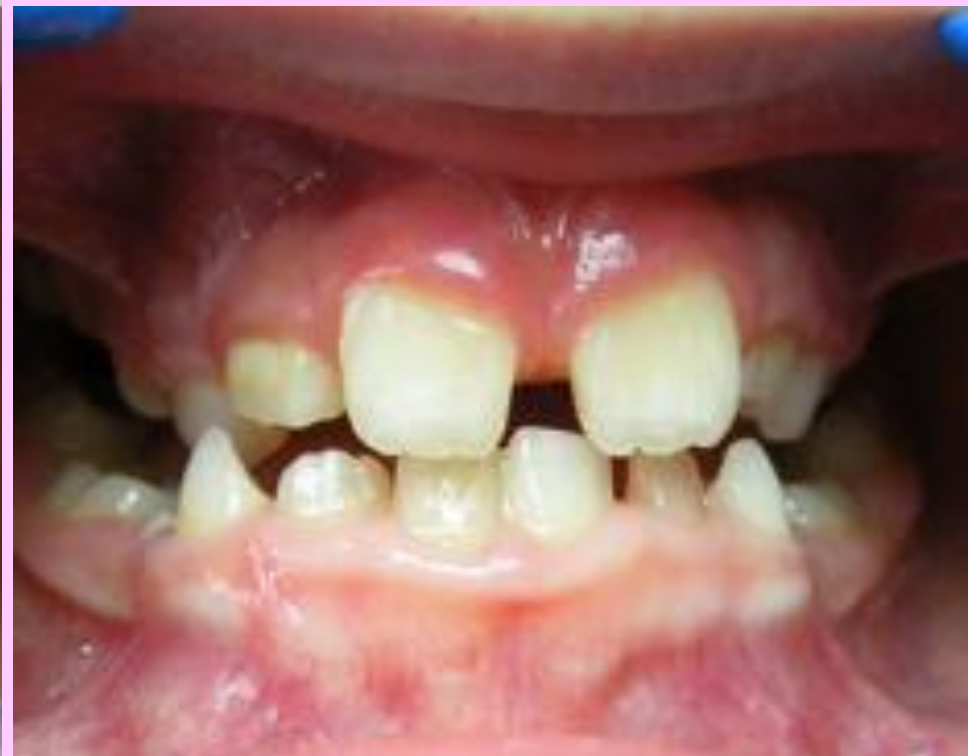
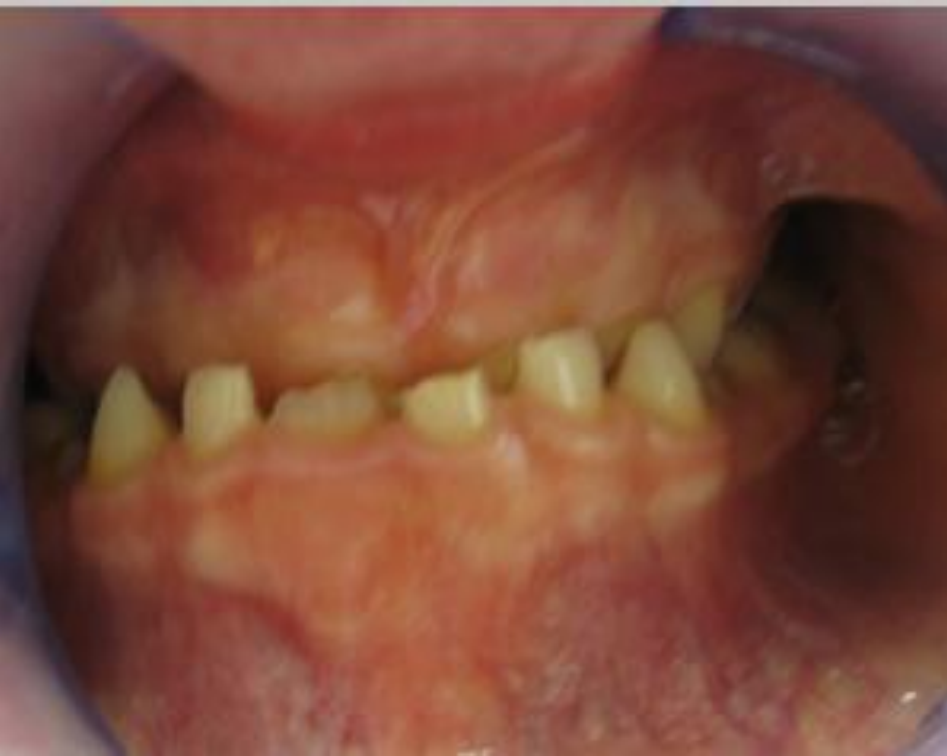
Treatment involved the wearing of an upper 3D appliance with screws to expand the palate and advance the pre-maxillary bone. (This holds the four front incisors.) The screw is turned 1/8mm per day and in conjunction with osteopathic work took 12 months to achieve this result.

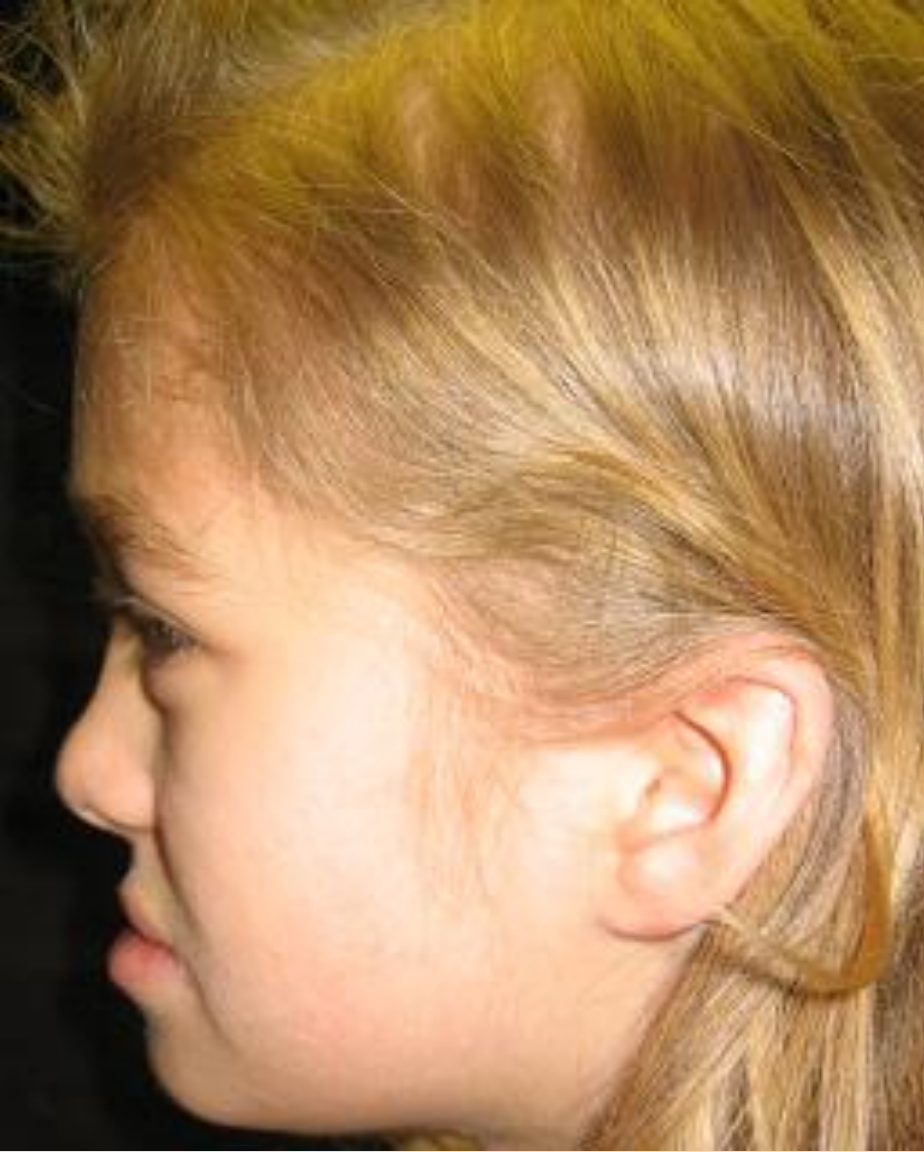

The work is not finished as several permanent have yet to erupt.





When the lower jaw is in front of the upper, the lower teeth sit in front in a reverse bite. This can only get worse with age as the growth of the upper jaw forward is inhibited and the growth of the lower jaw forward is stimulated. Early correction of this type of skeletal malocclusion is important as the longer it is left, the greater the chance that major orthognathic surgical repositioning of both jaws will be necessary later when growth has finished.



The result has given this girl an improved facial appearance and increased her self confidence